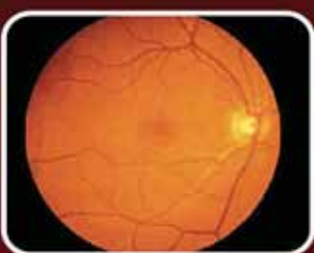
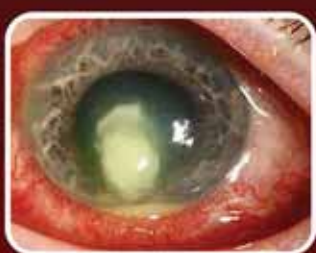
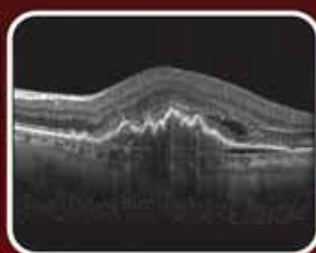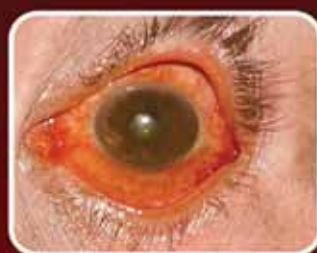Comprehensive

Revised Reprint

OPHTHALMOLOGY

As per the Competency-based Medical Education Curriculum (NMC)



9th
Edition

Complementary

• Online Resources

Quick Text Review

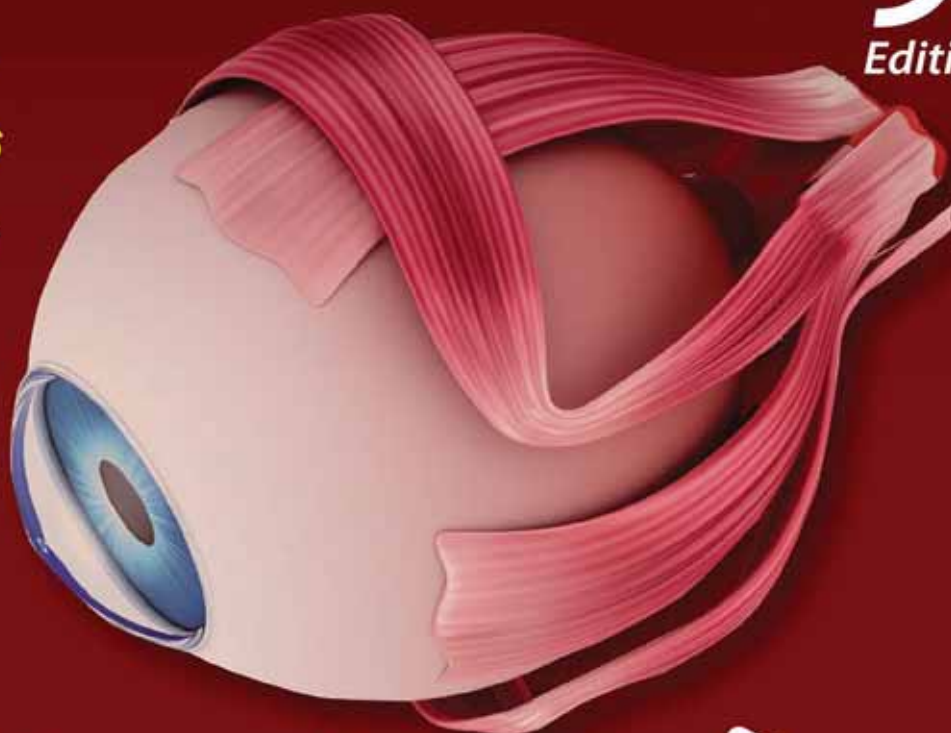
MCQs-NEET/NEXT Pattern

Clinical Skill Videos

Surgical Videos

• Practical Ophthalmology

• Logbook



A K Khurana

Scan to
Download the App



diginerve

A Jaypee Initiative

Your Guide at Every Step

Video Lectures | Notes | Self-Assessment



STUDY AUTHENTIC
Scratch the Hologram and
Scan the QR Code to Check the
Genuineness

Original Books Matter!!!
SAY NO TO PIRACY



JAYPEE

Preface

Contents—As per Competency-Based Medical Education (CBME) Curriculum of Ophthalmology

vii

xiii

Section I: Anatomy and Physiology of Eye

- | | |
|-----------------------------------|----|
| 1. Anatomy and Development of Eye | 03 |
| 2. Physiology of Eye and Vision | 14 |

Section II: Optics and Refraction

- | | |
|---|----|
| 3. Elementary and Physiological Optics | 23 |
| 4. Errors of Refraction, Accommodation and Asthenopia | 33 |

Section III: Diseases of Eye and Ocular Adnexa

- | | |
|------------------------------------|-----|
| 5. Diseases of Conjunctiva | 57 |
| 6. Diseases of Cornea | 90 |
| 7. Diseases of Sclera | 133 |
| 8. Diseases of Uveal Tract | 139 |
| 9. Diseases of Lens | 169 |
| 10. Glaucoma | 207 |
| 11. Diseases of Vitreous | 240 |
| 12. Diseases of Retina | 246 |
| 13. Neuro-ophthalmology | 291 |
| 14. Ocular Motility and Strabismus | 318 |
| 15. Disorders of Eyelids | 343 |
| 16. Diseases of Lacrimal Apparatus | 369 |
| 17. Diseases of Orbit | 383 |
| 18. Ocular Injuries | 406 |

Section IV: Ocular Therapeutics

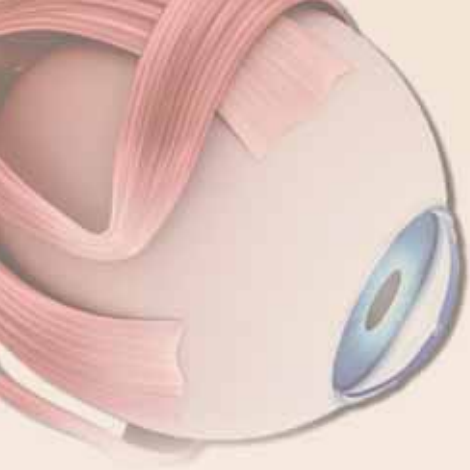
- | | |
|---|-----|
| 19. Ocular Pharmacology | 423 |
| 20. Lasers and Cryotherapy in Ophthalmology | 441 |

Section V: Systemic and Community Ophthalmology

- | | |
|-----------------------------|-----|
| 21. Systemic Ophthalmology | 449 |
| 22. Community Ophthalmology | 459 |

Annexure: NMC Guidelines for Eligibility to Appear in Examination 475

Index 479



Diseases of Cornea

Chapter Outline

ANATOMY AND PHYSIOLOGY

- Applied anatomy
- Applied physiology

CONGENITAL ANOMALIES

INFLAMMATIONS OF CORNEA

Infectious keratitis

- Bacterial keratitis
- Mycotic (Fungal) keratitis
- Viral keratitis
- Protozoal keratitis

Non-infectious keratitis

Allergic keratitis

Trophic Keratitis

- Neurotrophic keratitis
- Exposure keratitis

Peripheral ulcerative keratopathies

- Peripheral ulcerative keratitis associated with connective tissue diseases
- Mooren's ulcer
- Rosacea keratitis

Non-ulcerative keratitis

- Superficial
- Deep

CORNEAL DEGENERATIONS

- Age-related corneal degenerations
- Pathological corneal degenerations

CORNEAL DYSTROPHIES

- Epithelial and subepithelial dystrophies
- Bowman layer dystrophies
- Stromal corneal dystrophies
- Descemet membrane and endothelial corneal dystrophies

ECTATIC CONDITIONS OF CORNEA

- Keratoconus
- Keratoglobus
- Keratoconus posterior

ABNORMALITIES OF CORNEAL TRANSPARENCY

- Corneal oedema
- Corneal opacity
- Corneal vascularization

CORNEAL SURGERY

- Keratoplasty
- Refractive corneal surgery
- Phototherapeutic keratectomy
- Keratoprosthesis

Subject Competencies: The student should be able to

OP4.1 : Enumerate, describe and discuss the types and causes of corneal ulceration.

OP4.2 : Enumerate and discuss the differential diagnosis of infective keratitis.

OP4.3 : Enumerate the causes of corneal oedema.

OP4.6 : Enumerate the indications and the types of keratoplasty.

ANATOMY AND PHYSIOLOGY

■ APPLIED ANATOMY

Cornea is a transparent, avascular, watch-glass like structure. It forms anterior one-sixth of the outer fibrous coat of the eyeball.

Dimensions

- *Anterior surface* of cornea is elliptical with an average horizontal diameter of 11.7 mm and vertical diameter of 11 mm.
- *Posterior surface* of cornea is circular with an average diameter of 11.5 mm.

- *Thickness* of cornea in the centre varies from 0.5 to 0.6 mm while at the periphery it varies from 1 to 1.2 mm. Average corneal thickness is 540 micrometer and it is measured with the help of corneal pachymeter.
- *Radius of curvature.* The central 5 mm area of the cornea forms the powerful refracting surface of the eye. The anterior and posterior radii of curvature of this central part of cornea are 7.8 mm and 6.5 mm, respectively.
- *Refractive index* of the cornea is 1.376.
- *Refractive power* of the cornea is about 45 dioptres, which is roughly three-fourth of the total refractive power of the eye (60 dioptres). It is worth noting that refractive power

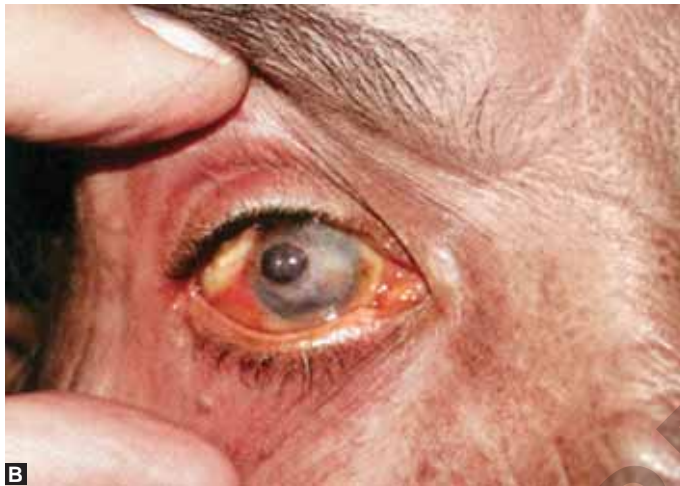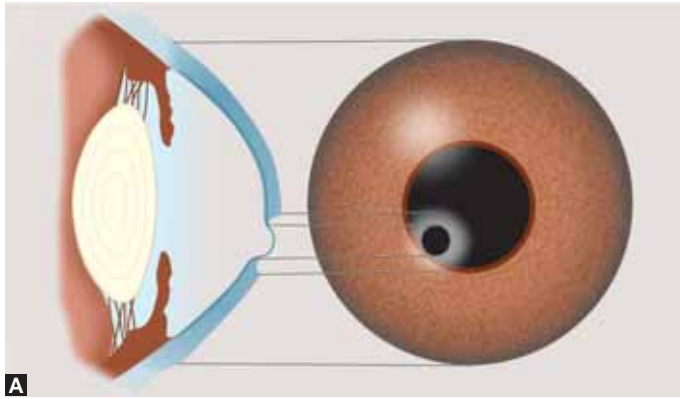


Fig. 6.3 Descemetocoele: A, Diagrammatic depiction; B, Clinical photograph

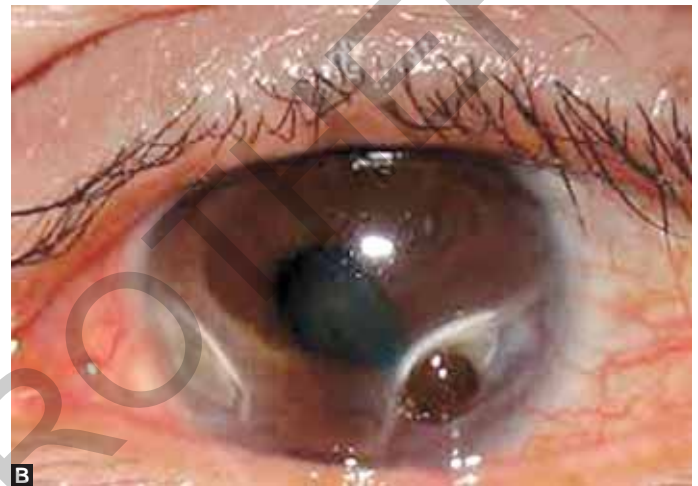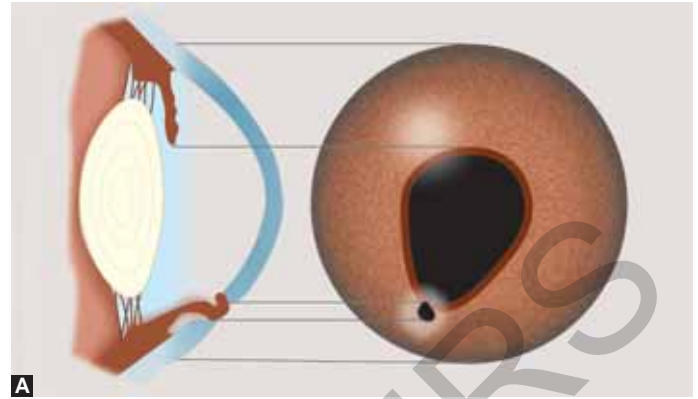


Fig. 6.4 Perforated corneal ulcer with prolapse of iris: A, Diagrammatic depiction; B, Clinical photograph

CLINICAL FEATURES

In bacterial infections, the outcome depends upon the virulence of organism, its toxins and enzymes, and the response of host tissue.

Broadly bacterial corneal ulcers may manifest as:

- Purulent corneal ulcer without hypopyon; or
- Hypopyon corneal ulcer.

In general, following symptoms and signs may be present:

Symptoms

1. Pain and foreign body sensation occurs due to mechanical effects of lids and chemical effects of toxins on the exposed nerve endings.
2. Watering from the eye occurs due to reflex hyperlacrimation.
3. Photophobia, i.e. intolerance to light results from stimulation of nerve endings.
4. Blurred vision results from corneal haze.
5. Redness of eyes occurs due to congestion of circumcorneal conjunctival vessels.

Signs

1. Swelling of lid of varying degree is present.
2. Blepharospasm may be moderate to severe.
3. Conjunctiva is chemosed and shows conjunctival hyperaemia and ciliary congestion.
4. Corneal ulcer usually starts as an epithelial defect associated with greyish-white circumscribed infiltrate (seen in early

stage). Soon the epithelial defect and infiltrate enlarges and stromal oedema develops. A well-established bacterial corneal ulcer is characterized by (Fig. 6.5):

- Yellowish-white area of ulcer which may be oval or irregular in shape.
- Margins of the ulcer are swollen and over hanging.
- Floor of the ulcer is covered by necrotic material.
- Stromal oedema is present surrounding the ulcer area.

Characteristic features produced by some of the common causative bacteria are as follows:

- *Staphylococcus aureus* and *Streptococcus pneumoniae* usually produce an oval, yellowish white densely opaque ulcer which is surrounded by relatively clear cornea (Fig. 6.5A).
- *Pseudomonas* species usually produce destructive enzymes (protease, lipase, elastase and exotoxin) which meet the corneal stroma and cause violent reaction in the anterior chamber. This results an irregular sharp ulcer with thick greenish mucopurulent exudate, diffuse liquefactive necrosis and semiopaque (ground glass) surrounding cornea. Such ulcers are usually associated with hypopyon, spread very rapidly and may even perforate within 48 to 72 hours.
- *Enterobacteriae* (*E. coli*, *Proteus* species, and *Klebsiella* species) usually produce a shallow ulcer with greyish white pleomorphic suppuration and diffuse stromal opalescence.

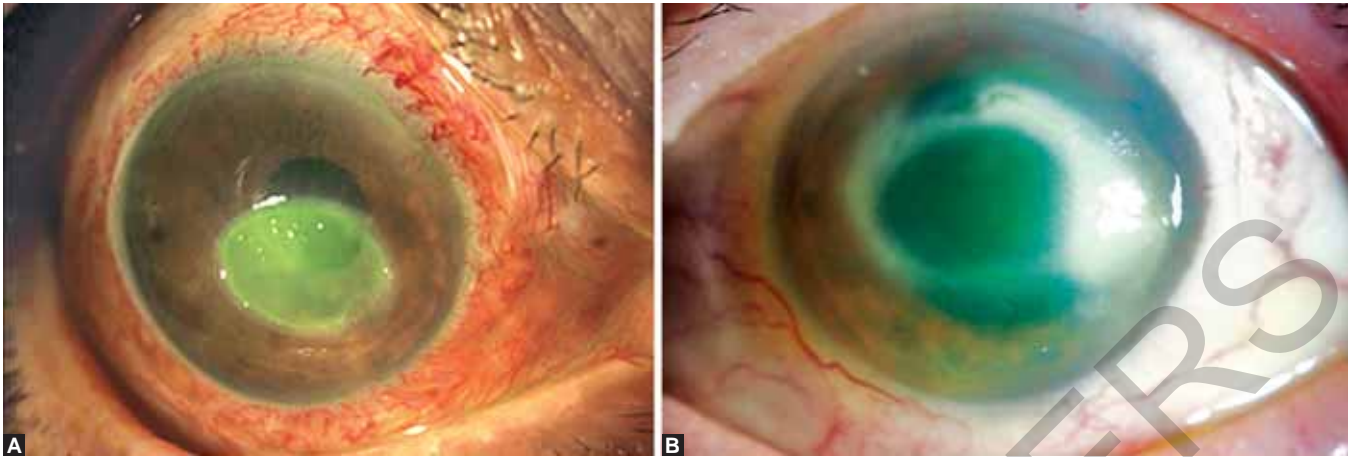


Fig. 6.5 Bacterial corneal ulcer: A, Oval ulcer; B, Ring-shaped ulcer

The endotoxins produced by these Gram-negative bacilli may produce ring-shaped corneal infiltrate (Fig. 6.5B).

5. **Anterior chamber** may or may not show pus (hypopyon). In bacterial corneal ulcers, the hypopyon remains sterile so long as the Descemet's membrane is intact.

6. **Iris** may be slightly muddy in colour.

7. **Pupil** may be small due to associated toxin-induced iritis.

8. **Intraocular pressure** may sometimes be raised (inflammatory glaucoma).

Hypopyon corneal ulcer

Causative organisms. It is customary to reserve the term 'hypopyon corneal ulcer' for the characteristic ulcer caused by *Pneumococcus* and the term 'corneal ulcer with hypopyon' for the ulcers associated with hypopyon due to other organisms such as *Staphylococci*, *Streptococci*, *Gonococci*, *Moraxella* and *Pseudomonas pyocyanea*. The characteristic hypopyon corneal ulcer caused by *Pneumococcus* is called *ulcus serpens*.

Source of infection for pneumococcal infection is usually the chronic dacryocystitis. Purulent keratitis with hypopyon is almost always exogenous, due to pyogenic organisms.

Factors predisposing to development of hypopyon. Two main factors which predispose to development of hypopyon in a patient with corneal ulcer are the virulence of the infecting organism and the resistance of the tissues. Hence, hypopyon ulcers are much more common in old debilitated or alcoholic subjects.

Mechanism of development of hypopyon. Corneal ulcer is often associated with some iritis owing to diffusion of bacterial toxins. When the iritis is severe the outpouring of leucocytes from the vessels is so great that these cells gravitate to the bottom of the anterior chamber to form a hypopyon. Thus, it is important to note that the hypopyon is sterile since the outpouring of polymorphonuclear cells is due to the toxins and not due to actual invasion by bacteria. Once the ulcerative process is controlled, the hypopyon is absorbed.

Clinical features

Symptoms are same as described above for bacterial corneal ulcer. However, it is important to note that during initial stage

of *ulcus serpens*, there is remarkably little pain. As a result, the treatment is often unduly delayed.

Signs. In general, the signs are same as described above for the bacterial ulcer.

Characteristic features of *ulcus serpens* are:

- *Ulcus serpens* is a greyish white or yellowish disc-shaped ulcer occurring near the centre of cornea (Fig. 6.6).

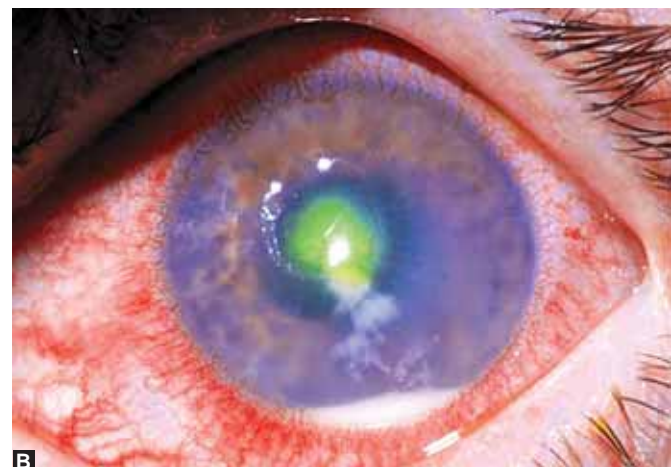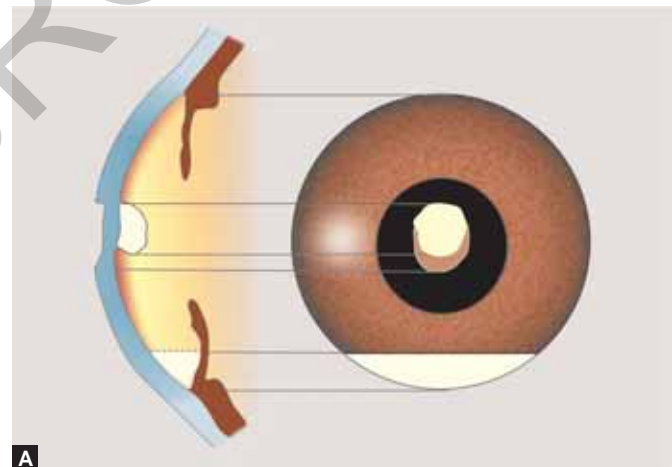


Fig. 6.6 Hypopyon corneal ulcer: A, Diagrammatic depiction; B, Clinical photograph

- *Ulcer has a tendency to creep* over the cornea in a serpiginous fashion. One edge of the ulcer, along which the ulcer spreads, shows more infiltration. The other side of the ulcer may be undergoing simultaneous cicatrization and the edges may be covered with fresh epithelium.
- *Violent iridocyclitis* is commonly associated with a definite hypopyon.
- *Hypopyon increases in size very rapidly* and often results in secondary glaucoma.
- *Ulcer spreads rapidly* and has a great tendency for early perforation.

Management

Management of hypopyon corneal ulcer is same as for other bacterial corneal ulcer.

Special points which need to be considered are:

- *Secondary glaucoma* should be anticipated and treated with 0.5% timolol maleate, BID eye drops and oral acetazolamide.
- *Source of infection*, i.e. chronic dacryocystitis if detected, should be treated by dacryocystectomy.

■ COMPLICATIONS OF CORNEAL ULCER

1. Toxic iridocyclitis. It is usually associated with cases of purulent corneal ulcer due to absorption of toxins in the anterior chamber.

2. Secondary glaucoma. It occurs due to fibrinous exudates blocking the angle of anterior chamber (inflammatory glaucoma).

3. Descemetocoele. Some ulcers caused by virulent organisms extend rapidly up to Descemet's membrane, which gives a great resistance, but due to the effect of intraocular pressure, it herniates as a transparent vesicle called the descemetocoele or keratocoele (See Fig. 6.3). This is a sign of impending perforation and is usually associated with severe pain.

4. Perforation of corneal ulcer. Sudden strain due to cough, sneeze or spasm of orbicularis muscle may convert impending perforation into actual perforation (See Fig. 6.4). Following perforation, immediately pain is decreased and the patient feels some hot fluid (aqueous) coming out of eyes.

Sequelae of corneal perforation include:

- *Prolapse of iris.* It occurs immediately following perforation in a bid to plug it.
- *Subluxation or anterior dislocation of lens* may occur due to sudden stretching and rupture of zonules.
- *Anterior capsular cataract.* It is formed when the lens comes in contact with the ulcer following a perforation in the pupillary area.
- *Corneal fistula.* It is formed when the perforation in the pupillary area is not plugged by iris and is lined by epithelium which gives way repeatedly. There occurs continuous leak of aqueous through the fistula.
- *Purulent uveitis, endophthalmitis* or even *panophthalmitis* may develop due to spread of intraocular infection.
- *Intraocular haemorrhage* in the form of either vitreous haemorrhage or expulsive choroidal haemorrhage may occur in some patients due to sudden lowering of intraocular pressure.

5. Corneal scarring. It is the usual end result of healed corneal ulcer. Corneal scarring leads to permanent visual impairment ranging from slight blurring to total blindness. Depending upon

the clinical course of ulcer, corneal scar noted may be nebula, macula, leucoma, ectatic cicatrix or keratectasia, adherent leucoma or anterior staphyloma (for details See page 126).

■ MANAGEMENT OF A CASE OF CORNEAL ULCER

Since corneal ulcer is sight threatening, it needs urgent treatment by identification and eradication of causative bacteria. Preferably such patients should be hospitalized. The management includes:

- Clinical evaluation,
- Laboratory investigations, and
- Treatment.

A. Clinical evaluation

Each case with corneal ulcer should be subjected to:

- 1. Thorough history taking** to elicit mode of onset.
- 2. General physical examination**, especially for built, nourishment, anaemia and any immunocompromising disease.
- 3. Ocular examination** should include:

- *Diffuse light examination* for gross lesions of lids, conjunctiva and cornea including testing for sensations.
- *Regurgitation test* and *syringing* to rule out lacrimal sac infection.
- *Biomicroscopic examination* after staining of corneal ulcer with 2% freshly prepared aqueous solution of fluorescein dye or preferably sterilised fluorescein impregnated filter paper strip. Ulcer area stains as brilliant green, which looks opaque green when seen with blue filter. Note site, size, shape, depth, margin, floor and vascularization of corneal ulcer. On biomicroscopy also note presence of keratic precipitates at the back of cornea, depth and contents of anterior chamber, colour and pattern of iris and condition of crystalline lens.

B. Laboratory investigations

1. Routine laboratory investigations such as haemoglobin, TLC, DLC, ESR, blood sugar, complete urine and stool examination should be carried out in each case.

2. Microbiological investigations. These studies are essential to identify causative organism, confirm the diagnosis and guide the treatment to be instituted. Material for such investigations is obtained by scraping the base and margins of the corneal ulcer (under local anaesthesia, using 2% xylocaine or preferably paracain) with the help of a modified Kimura spatula or by simply using the bent tip of a 20 gauge hypodermic needle. The material obtained is used for the following investigations:

- *Gram and Giemsa stained smears* for possible identification of infecting organisms.
- *10% KOH wet preparation* for identification of fungal hyphae.
- *Calcofluor white (CFW) stain* preparation is viewed under fluorescence microscope for fungal filaments, the walls of which appear bright apple green.
- *Culture on blood agar* medium for aerobic organisms.
- *Culture on Sabouraud's dextrose agar* medium for fungi.

C. Treatment

I. Treatment of uncomplicated corneal ulcer

Treatment of corneal ulcer can be discussed under three lesions:

- Definitive treatment of the cause.

Signs

I. Corneal signs

Three distinct patterns of epithelial keratitis seen are: punctate epithelial keratitis, dendritic ulcer and geographical ulcer.

1. Punctate epithelial keratitis (Figs 6.9A and B). The initial epithelial lesions of recurrent herpes resemble those seen in primary herpes and may be either in the form of fine or coarse superficial punctate lesions. The corneal vesicles coalesce and erupt to form dendritic or geographic ulcer (corneal vesicles).

2. Dendritic ulcer (Figs 6.9C and D). Dendritic ulcer is a typical and most common lesion of recurrent epithelial keratitis.

- The ulcer is of an irregular, zigzag linear branching shape.
- The branches are generally knobbed at the ends.
- Floor of the ulcer stains with fluorescein and the virus-laden cells at the margin take up rose bengal.
- There is an associated marked diminution of corneal sensations.

3. Geographic ulcer (Figs 6.9E and F). Sometimes, the branches of dendritic ulcer enlarge and coalesce to form a large epithelial ulcer with a 'geographic' or 'amoeboid' configuration, hence the name. The use of steroids in dendritic ulcer hastens the formation of geographic ulcer.

II. Other signs associated with epithelial keratitis

These include:

- *Eyelid vasicular lesions*, may sometimes coincide with epithelial ulceration.
- *Follicular conjunctivitis*, may also be associated in some cases. Further, topical antiviral drugs may also cause this.
- *Anterior chamber reaction*, of mild intensity, may be also be noticed in some cases.
- *Raised intraocular pressure*, is not uncommon.

Treatment

A. Treatment of epithelial keratitis

I. Definitive treatment

1. Antiviral drugs are the first choice presently. Any one of the following drugs may be given:

- *Acycloguanosine* (Aciclovir) 3% ointment: 5 times a day for 14–21 days. It is least toxic and most commonly used antiviral drug. It penetrates intact corneal epithelium and stroma, achieving therapeutic levels in aqueous humour, and can therefore be used to treat herpetic keratitis.
- *Ganciclovir* (0.15% gel), 5 times a day until ulcer heals and then 3 times a day for 5 days. It is more toxic than aciclovir.
- *Trifluorothymidine* 1% drops: Two hourly until ulcer heals and then 4 times a day for 5 days.
- *Adenine arabinoside* (Vidarabine) 3% ointment: 5 times a day until ulcer heals and then 3 times a day for 5 days.

2. Mechanical debridement of the involved area along with a rim of surrounding healthy epithelium with the help of sterile cotton applicator under magnification helps by removing the virus-laden cells.

Before the advent of antiviral drugs, it was the treatment of choice. Now it is reserved for resistant cases, cases with noncompliance and those allergic to antiviral drugs.

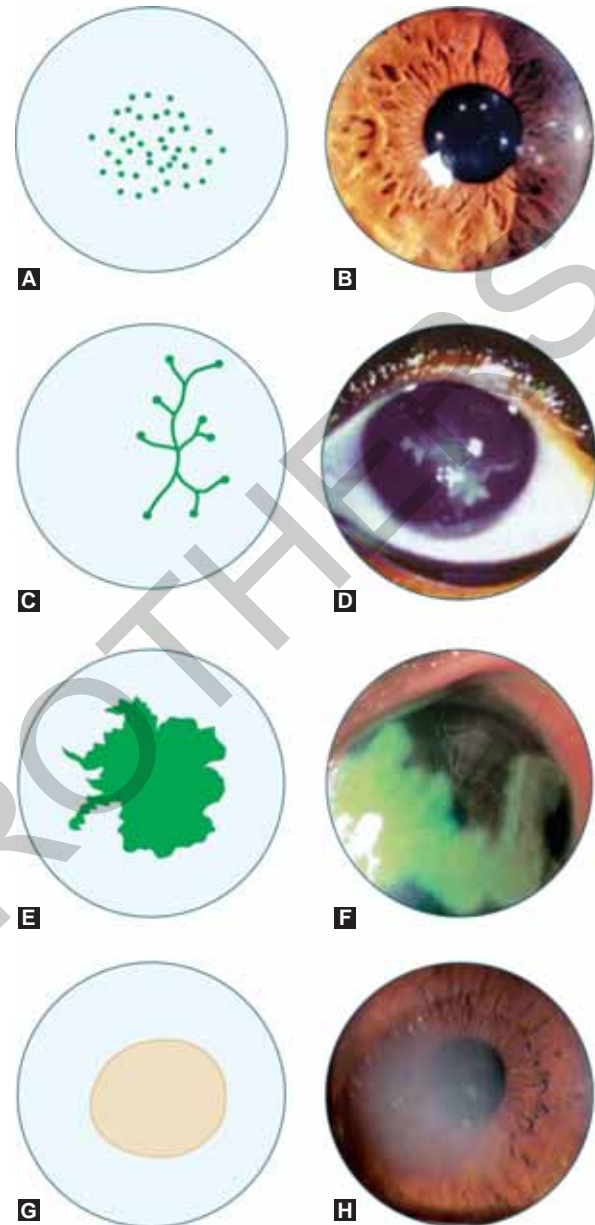


Fig. 6.9 Lesions of recurrent herpes simplex keratitis; diagrammatic depiction and Clinical photograph: A and B, Punctate epithelial keratitis; C and D, Dendritic ulcer; E and F, Geographical ulcer; G and H, Disciform keratitis

3. Systemic antiviral drugs for a period of 10 to 21 days are increasingly being considered for recurrent and even acute cases in following doses:

- Acyclovir 400 mg p.o. tid to bid, or
- Famcyclovir 250 mg p.o. bid, or
- Valacyclovir 500 mg p.o. bid.

B. Non-specific supportive therapy and physical and general measures are same as for bacterial corneal ulcer (See page 99).

II. Stromal keratitis

Stromal keratitis accounts for 20–48% cases of recurrent ocular HSV disease. It occurs in two forms:

- *Epithelial ridges*, i.e. raised epithelial lines, initially, typical reticular pattern is seen due to underlying radial keratoneuritis.
 - *Pseudodendrites* formation, occurs and at this stage, it is commonly mistaken for herpes simplex keratitis (Fig. 6.12A).
 - *Epithelial and subepithelial curvilinear opacities* (usually fine).
- 2. Radial keratoneuritis** appearing as liner stromal infiltrates (Fig. 6.12B), reported in 50% cases, seems to be pathognomonic early sign. It is thought to be the cause of severe pain disproportionate to inflammation.
- 3. Limbal lesions** include: *Limbitis* which is reported in majority of cases in early stages of infection.
- 4. Stromal lesions** occur over a period of week and include:
- *Patchy and satellite* stromal infiltrates.
 - *Ring infiltrates*, central or paracentral are formed as a result of coalescence of patchy infiltrates. These are associated, with overlying epithelial defects and underlying keratic precipitates (Fig. 6.12C).
 - *Ring abscess* (Fig. 6.12D) associated with stromal necrosis and hypopyon may occur in late stages and mimics any suppurative keratitis. Corneal melting may occur in the periphery. Corneal vascularization is typically absent.

- *Persistent corneal inflammation* may occur due to necrotic protozoa (*Acanthamoeba* antigen) rather than viable organism and may result in scarring.
- 4. Scleritis**, usually anterior diffuse or nodular, can be contiguous with keratitis. Rarely posterior scleritis with optic neuritis is also reported.
- 5. Anterior chamber inflammation** may manifest as anterior uveitis and hypopyon.

Differential diagnosis

1. *Viral keratitis*. In early stages, both epithelial lesions and early infiltrates, especially pseudodendrites, are often mistaken for viral keratitis.
2. *Fungal keratitis* can also be misdiagnosed when ring infiltrates are associated with hypopyon.
3. *Suppurative keratitis* due to bacterial or other causes may be misdiagnosed in stage of stromal necrosis, and ring abscess formation.

Diagnosis

1. *Clinical diagnosis*. It is difficult and usually made by exclusion with strong clinical suspicion out of the non-responsive patients being treated for herpetic, bacterial or fungal keratitis. Non-suppurative keratitis in a contact lens wearer must arise suspicion.

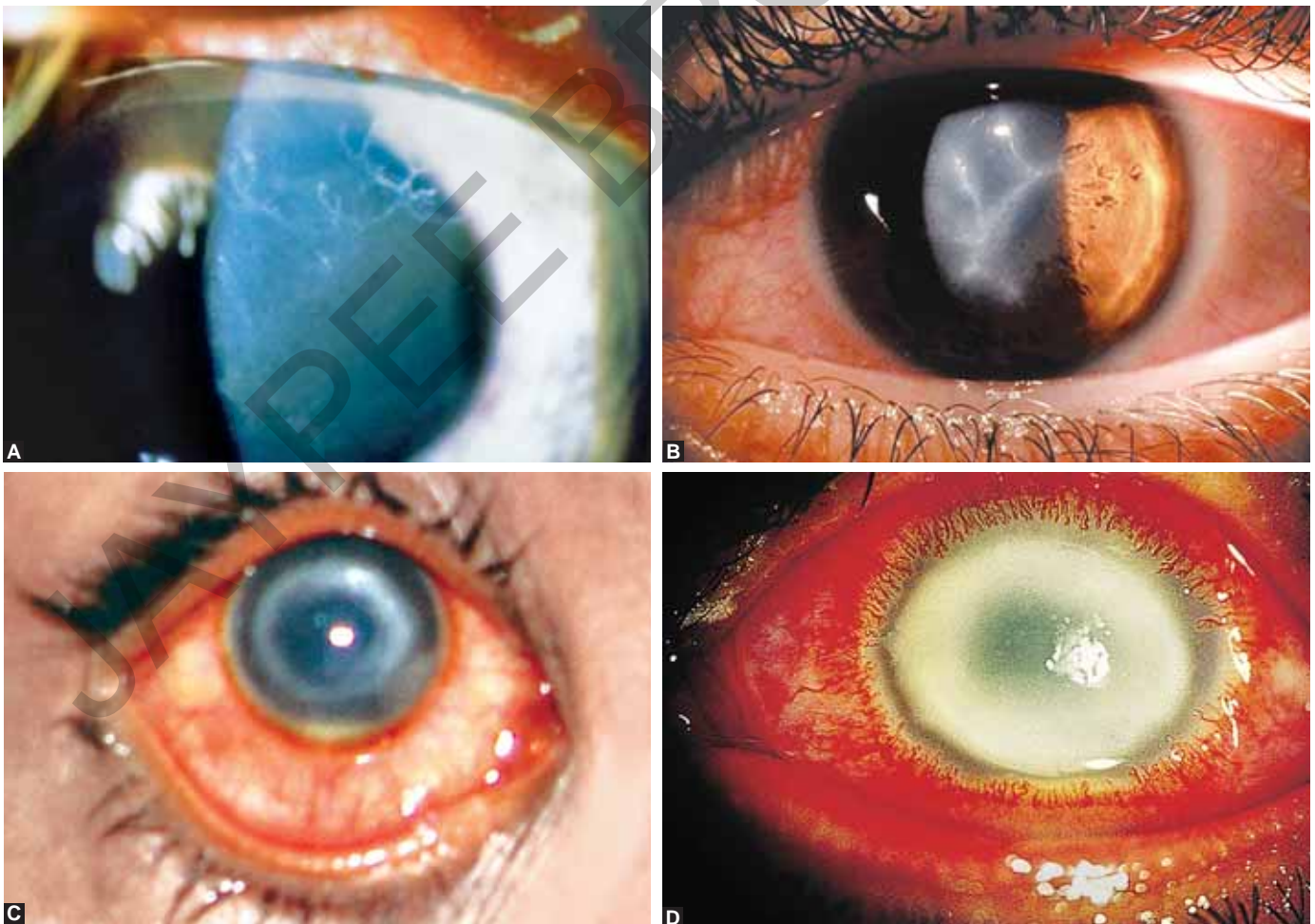


Fig. 6.12 *Acanthamoeba* keratitis: A, *Acanthamoeba* pseudodendrites; B, Radial keratoneuritis; C, Ring infiltrate; D, Ring abscess

- Marginal keratitis (catarrhal ulcer) of Staphylococcal hypersensitivity (See page 100),
- Terrien marginal degeneration (See page 118),
- Pellucid marginal degeneration (See page 118),
- Phlyctenular keratitis (See page 78), and
- Dellen.

■ PERIPHERAL ULCERATIVE KERATITIS ASSOCIATED WITH CONNECTIVE TISSUE DISEASES (MARGINAL KERATOLYSIS)

Causes

Peripheral corneal ulceration and/or melting of corneal tissue is not of infrequent occurrence in patients suffering from connective tissue diseases such as:

- Rheumatoid arthritis,
- Systemic lupus erythematosus (SLE),
- Polyarteritis nodosa, and
- Wegener's granulomatosis.

Clinical features

- *Peripheral acute corneal ulceration* with rapid progression, usually in one sector, associated with inflammation at the limbus in one or both eyes.
- *Peripheral corneal guttering* or thinning may involve entire corneal periphery (contact lens cornea).
- *Peripheral corneal melting* may result in descemetocoele formation or even perforation.
- *Corneal ulceration* may be the first manifestation of the systemic disease and there may be associated systemic features of any of the causative disease.

Treatment

Such corneal ulcers are usually indolent and difficult to treat.

1. **Topical medication** include, antibiotics, cycloplegics and frequent instillation of lubricating drops. Topical steroids may be used with great caution, but not in the presence of significant thinning.

2. **Systemic medication** includes immunosuppressants (corticosteroids, or methotrexate, cyclophosphamide), doxycycline and oral vitamin C (to promote a healing stromal environment).

3. **Surgical measures** needed include:

- *Excision* of adjacent inflamed conjunctiva,
- *Bandage contact lens* or conjunctival flap for impending perforation,
- *Application of cyanoacrylate* tissue adhesive or peripheral tectonic keratoplasty for actual perforation.

■ MOOREN'S ULCER

Mooren's ulcer (chronic serpinginous or rodent ulcer) is a severe inflammatory peripheral ulcerative keratitis.

Etiology

Exact etiology is not known. Most probably it is an *autoimmune disease* (antibodies against corneal epithelium have been demonstrated in serum).

Clinical features

Two clinical varieties of Mooren's ulcer have been recognised.

1. *Benign or limited form* which is usually unilateral, affects the elderly Caucasians and is characterised by a relative slow progress.

2. *Virulent type* also called the *progressive form* is bilateral, more often occurs in young African patients. The ulcer is rapidly progressive with a high incidence of scleral involvement.

Symptoms. These include severe pain, photophobia, lacrimation and defective vision.

Signs. Features of Mooren's ulcer are shown in Fig. 6.14.

- It is a superficial ulcer which starts at the corneal margin as patches of grey infiltrates which coalesce to form a shallow furrow over the whole cornea.
- *Peripheral ulcer* is associated with *undermining* of the epithelium and superficial stromal lamellae at the advancing border which forms a characteristic whitish overhanging edge. Base of the ulcer soon becomes vascularized. The spread may be self-limiting or progressive.
- *At the end-stage*, the cornea is thinned and conjunctivalised.
- *Ulcer rarely perforates* and the sclera remains uninvolved.

Treatment

Since exact etiology is still unknown, its treatment is highly unsatisfactory. Following measures may be tried:

1. *Topical corticosteroids* instilled every 2–3 hours are tried as initial therapy with limited success.
2. *Immunosuppressive therapy* with systemic steroids may be of help. Immunosuppression with *cyclosporin* or other cytotoxic agents may be quite useful in virulent type of disease.

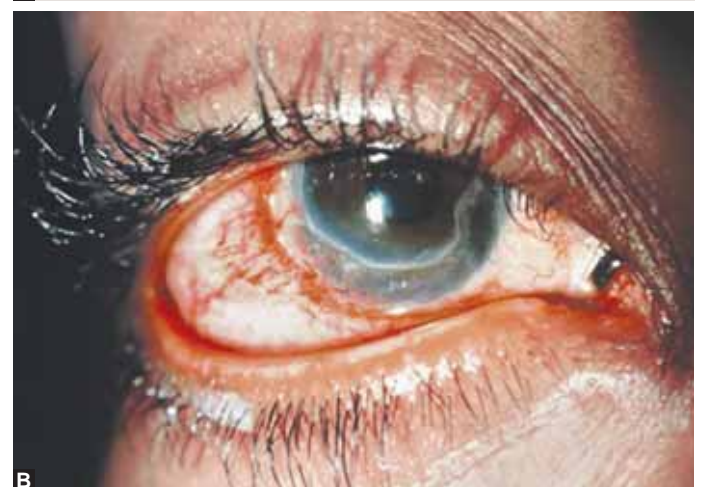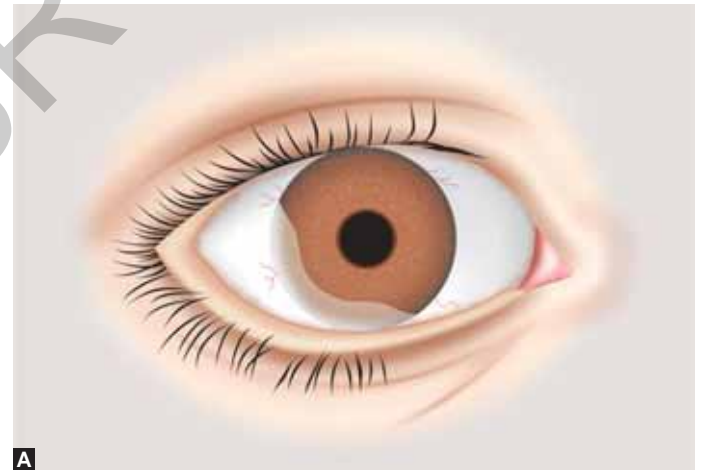


Fig. 6.14 Mooren's ulcer: A, Diagrammatic depiction; B, Clinical photograph

Inheritance is autosomal recessive.

Signs and symptoms are similar to CHED 1 except:

- The condition is more common and severe than CHED 1.
- Nystagmus is often associated.

iii. X-linked Endothelial Corneal Dystrophy

Onset and course. X-linked endothelial corneal dystrophy (XECD) occurs congenitally and is a progressive condition in males and non-progressive in females.

Genetic locus is Xq25 and the **gene** involved is unknown.

Inheritance is X-chromosomal dominant.

Signs and symptoms are as below:

Male patients have blurring of vision associated with:

- **Corneal clouding** since birth ranging from a diffuse haze to a ground-glass, milky appearance.
- **Moon crater-like** endothelial changes.
- **Subepithelial band keratopathy** combined with moon crater-like endothelial changes.
- **Nystagmus** may be associated.

Female patients are asymptomatic having only *moon crater-like* endothelial changes.

ECTATIC CONDITIONS OF CORNEA

■ KERATOCONUS

Keratoconus (conical cornea) (Figs 6.29A to C) is a progressive non-inflammatory bilateral (85%) ectatic condition of cornea in its axial part. It usually starts at puberty and progresses slowly.

Etiopathogenesis

Exact etiology is not known. It is being implicated that some factors produce molecular changes in the corneal tissue which in turn derange corneal biomechanisms and act as precursor for the corneal thinning and development of keratoconus formation.

Factors producing molecular changes in the cornea include:

1. **Genetic factors** such as genetic predisposition and genetic mutation), and
2. **Environmental factors** such as:
 - **Eye rubbing** is being considered an important factor and accounts for the association of keratoconus with vernal keratoconjunctivitis and Down syndrome.
 - **Other environmental factors** include contact lens use (especially RGP), UV light, atopy and some hormonal changes.

Molecular changes in cornea include:

- Defective formation/destruction of extracellular matrix
- Abnormal collagenase activity
- Increased levels of proteases and catabolic enzymes in the basal epithelial cells
- Decreased levels of proteinase inhibition

Histopathological changes in cornea, produced by molecular changes leading to thinning and development of keratoconus are as below:

- **Corneal epithelium** shows thinning and breaks in the basement membrane
- **Bowman's membrane** shows Z-shaped interruptions with migration of corneal epithelium in the anterior corneal stroma

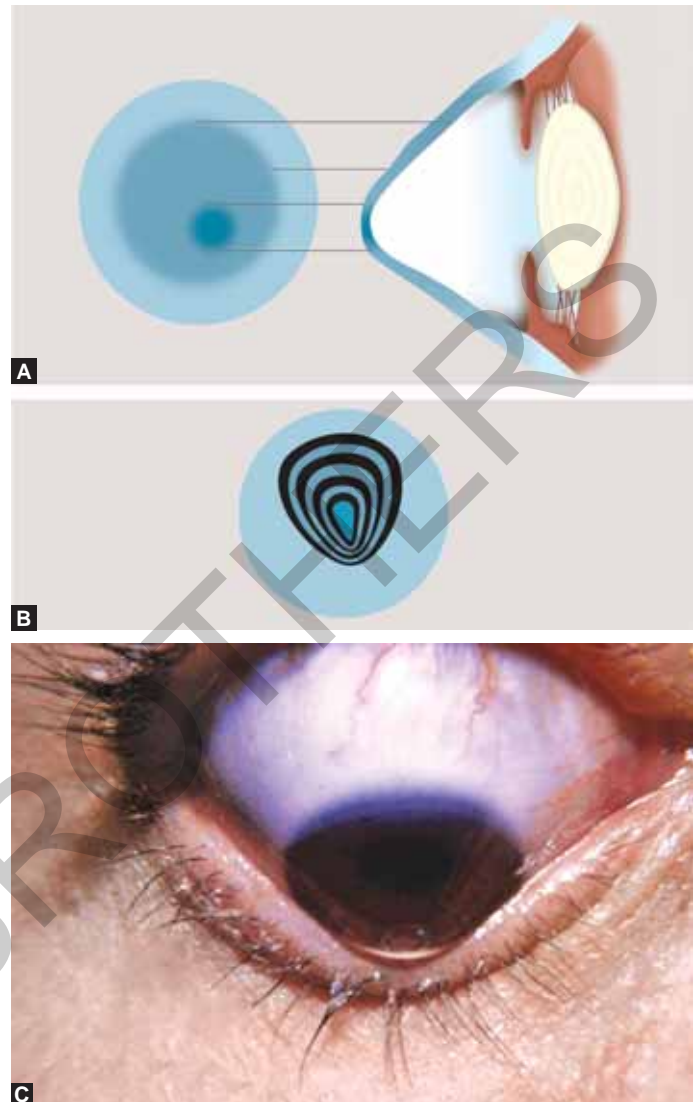


Fig. 6.29 Keratoconus showing: A, Diagrammatic depiction of configuration of cone-shaped cornea; B, Irregular circles on Placido disc examination; C, Clinical photograph (note Munson's sign)

- **Corneal stroma** shows decreased collagen lamella and thinning without collagenolysis.

Essential pathological changes are progressive thinning and ectasia which occur as a result of defective synthesis of mucopolysaccharide and collagen tissue.

Associations. Keratoconus may be associated with:

- **Ocular conditions**, e.g. ectopia lentis, congenital cataract, aniridia, retinitis pigmentosa, vernal keratoconjunctivitis (VKC), atopic keratoconjunctivitis, Leber's congenital amaurosis, floppy eyelid syndrome and corneal endothelial dystrophy.
- **Systemic conditions**, e.g. Marfan's syndrome, atopy, asthma, eczema, hay fever. Down's syndrome, Ehlers-Danlos syndrome, osteogenesis imperfecta and mitral valve prolapse.

Clinical features

Symptoms. Patient presents with:

Progressive defective vision primarily due to progressive myopia and irregular astigmatism.

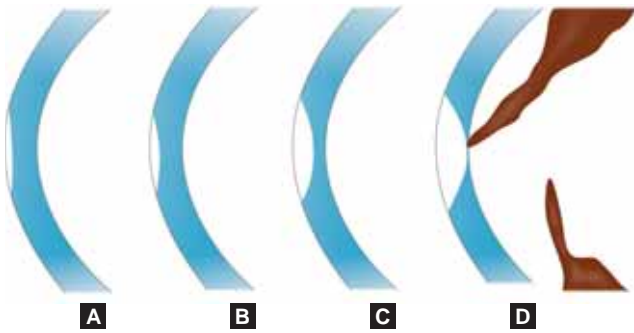


Fig. 6.31 Diagrammatic depiction of corneal opacity: A, Nebular; B, Macular; C, Leucomatous; D, Adherent leucoma

2. Macular corneal opacity. It is a semi-dense opacity produced when scarring involves about half the corneal stroma (Figs 6.31B and 6.32B).

3. Leucomatous corneal opacity (leucoma simplex). It is a dense white opacity which results due to scarring of more than half of the stroma (Figs 6.31C and 6.32C).

4. Adherent leucoma. It results when healing occurs after perforation of cornea with incarceration of iris (Figs 6.31D and 6.32D).

5. Corneal facet. Sometimes, the corneal surface is depressed at the site of healing (due to less fibrous tissue); such a scar is called facet.

6. Kerectasia. In this condition, corneal curvature is increased at the site of opacity (bulge due to weak scar).

7. Anterior staphyloma. An ectasia of pseudocornea (the scar formed from organised exudates and fibrous tissue covered with epithelium) which results after total sloughing of cornea, with iris plastered behind it is called *anterior staphyloma* (Figs 6.33A and B).

Secondary changes in corneal opacity which may be seen in long-standing cases include: hyaline degeneration, calcareous degeneration, pigmentation and atheromatous ulceration.

Treatment

1. Optical iridectomy. It may be performed in cases with central macular or leucomatous corneal opacities, provided vision improves with pupillary dilatation.

2. Phototherapeutic keratectomy (PTK) performed with excimer laser is useful in superficial (nebular) corneal opacities.

3. Keratoplasty provides good visual results in uncomplicated cases with corneal opacities, where optical iridectomy is not of much use.

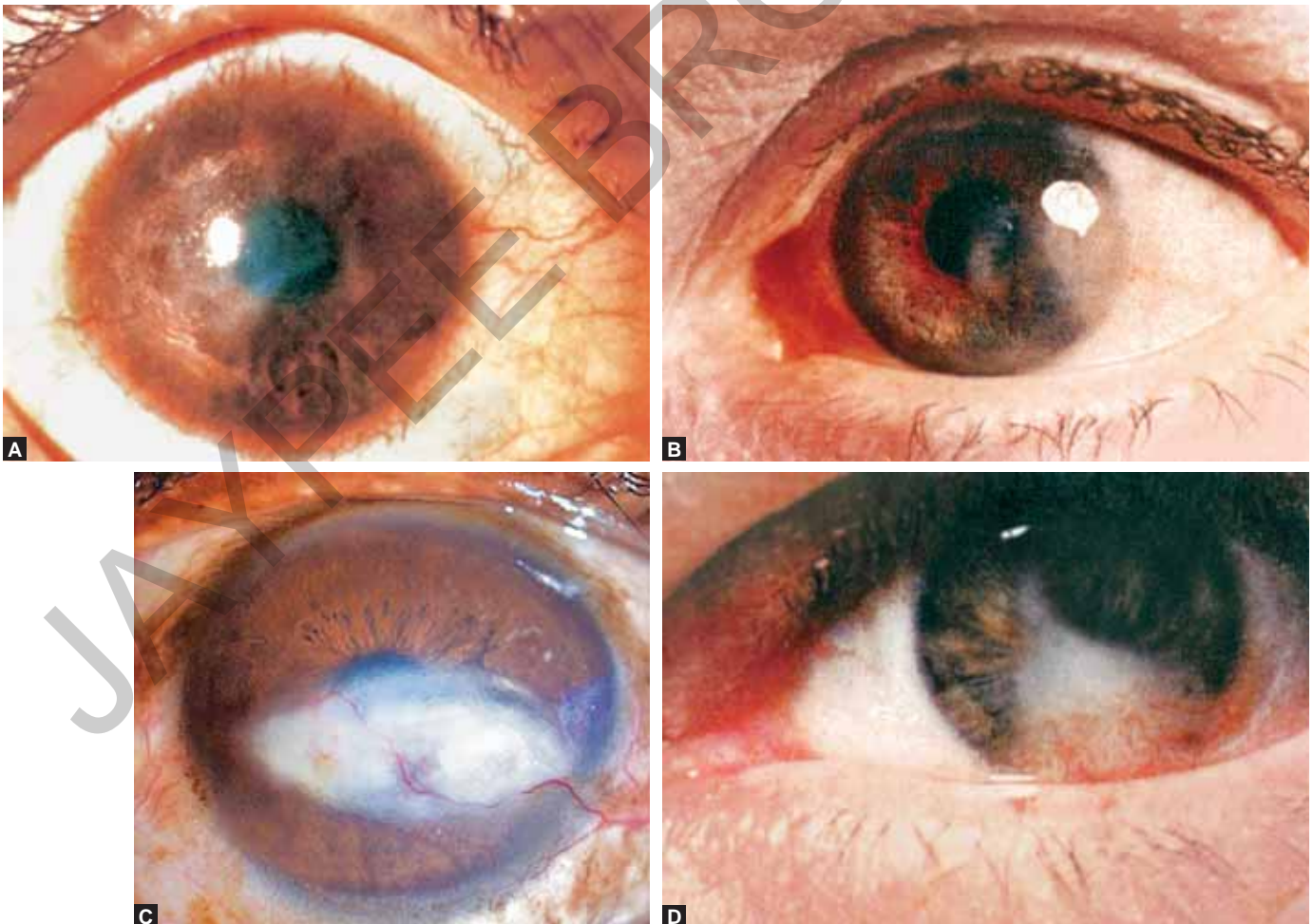


Fig. 6.32 Clinical photographs of corneal opacity: A, Nebular; B, Macular; C, Leucomatous; D, Adherent leucoma

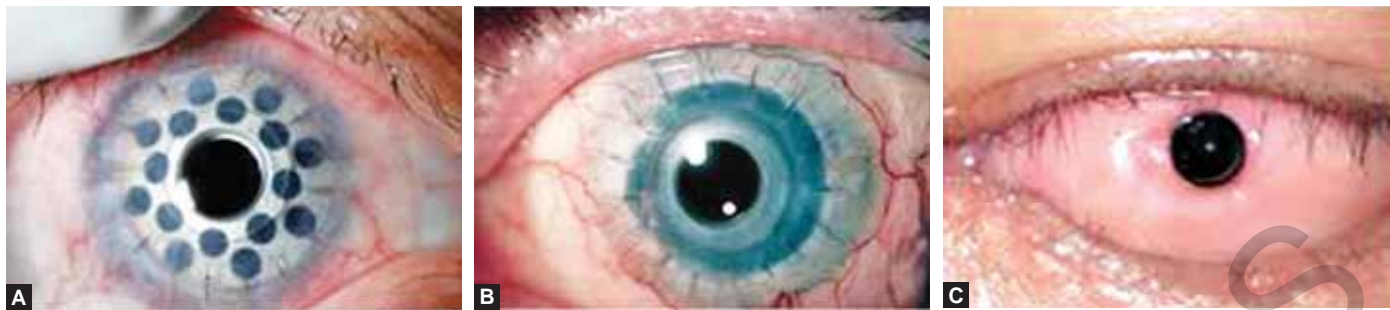


Fig. 6.36 Keratoprosthesis: A, Boston K-Pro type I; B, Alfa Cor; C, Osteo-odonto

is a junction zone between the skirt and central optic and serves as a permanent bond. It has a refractive power close to that of human cornea. It is used less frequently because it requires a 2-stage procedure and there are problems with the retention as well.

3. **Modified Osteo-odonto-keratoprosthesis, i.e. MOOKP** (Fig. 6.36C), is fixed with the help of patients own tooth root and alveolar bone. It is also used less frequently because it requires complex surgical procedure to be performed in three stages.

4. **Chondro-keratoprosthesis** is fixed with patients own cartilage.

5. **Onycho-keratoprosthesis** is fixed with patient's nails.

6. **Stanford keratoprosthesis** is a recently introduced device which incorporates the grafting of bio-active factors with a change in the bulk material design.

7. **Singh and Worst collar-stud keratoprosthesis** is fixed with stainless steel sutures, and is not popular presently.

Complications include:

- Extrusion of prosthesis,
- Intractable glaucoma,
- Retroprosthetic membrane formation,
- Uveitis, and
- Retinal detachment.

Review Questions

Short Answer Questions

1. Describe briefly pathogenesis of bacterial corneal ulcer.
2. Write short note on hypopyon corneal ulcer.
3. Write shortly about management of bacterial corneal ulcer.
4. Write briefly about herpes simplex epithelial keratitis.
5. Write short note on herpes zoster ophthalmicus (HZO).
6. Write short note on neuroparalytic keratitis.
7. Write short note on keratoconus.

Long Answer Questions

1. A 50-year-old male presents with history of trauma with a plant twig followed by moderate pain, watering, defective vision, and whitish discoloration of cornea. Describe the differential diagnosis of the condition.
2. A 60-year-old debilitated sick looking male patient presents with pain and skin vesicles limited to right side of forehead and upper eyelid followed by redness, watering, and defective vision in right eye. Describe etiology, clinical features, and management of the condition.

Comprehensive OPHTHALMOLOGY

Better understanding of **Competency-based Medical Education (CBME)** curriculum has necessitated the early revision. So, ninth edition has been revised, updated with recent advances incorporated in every section. However, the layout of the book which has been appreciated by the medical students is retained as such, with text arranged in five sections.

Section I: Anatomy and Physiology of Eye includes two chapters one each on Anatomical and Physiological aspects of Eye and Ocular Adnexa.

Section II: Optics and Refraction comprises two chapters one each on Elementary and Physiological Optics, and Errors of Refraction, Accommodation and Asthenopia.

Section III: Diseases of Eye and Ocular Adnexa exhibits an exhaustive and thorough exposition of the text on disorders of eyeball, ocular adnexa and visual pathway in fourteen chapters.

Section IV: Ocular Therapeutics includes a chapter on Ocular Pharmacology and another chapter on Lasers and Cryotherapy in Ophthalmology.

Section V: Systemic and Community Ophthalmology covers updated text on these topics in two chapters.

Practical Ophthalmology, in the 9th edition, has been compiled as a separate complementary book with the *Comprehensive Ophthalmology*. It will serve as a handbook for use during clinical postings. As, it provides exact insights and topic essential for practical examinations, so, it will also be useful for quick comprehension during final practical examinations. This book has been updated with following incorporations:

- **AETCOM** (Attitude, Ethics and Communication skills), which is unique and essential concept under CBME curriculum, has been introduced in the very first chapter.
- **Case studies** have been incorporated liberally in this chapter, keeping in view the patient centric, Competency-based Medical Education (CBME) curriculum, 2018.
- **DOAP** (Demonstrate, Observe, Assess and Perform) concept has been incorporated appropriately with competency number mapped.
- **Skill assessment**, one of the suggested assessment method in new CBME curriculum has also been included.
- **OSPE** (Objectively Structured Practical Examination) and **OSCE** (Objectively Structured Clinical Examination) have also been incorporated.

Logbook, which provides a clear setting of learning objectives, as per latest guidelines of NMC under CBME curriculum as a complementary accompaniment.

Review of Ophthalmology, a companion to the textbook which offers quick comprehension at a glance and an opportunity for self-assessment with latest multiple choice questions (MCQs), has been updated with latest text and picture based MCQs. In ninth edition, *Review of Ophthalmology* has been given as an online complementary resource with an added feature of **Clinical Skill Videos and Surgical Videos**.

These **unique salient features** of this book make it an authentic text for theory, practical and postgraduate entrance examinations. It will also serve as a readily available online resource for residents in ophthalmology as well as practicing ophthalmologists.

AK Khurana MS FAICO CTO (London) is currently Professor and Head, Department of Ophthalmology, SGT Medical College, Hospital and Research Institute, Gurugram, Haryana, India. He is Former Senior Professor and Head, Regional Institute of Ophthalmology, Postgraduate Institute of Medical Sciences (PGIMS), University of Health Sciences, Rohtak, Haryana. He has been teaching ophthalmology for the last more than four decades. In addition to this book, he has written many popular books. His other books, namely *Anatomy and Physiology of Eye, Theory and Practice of Squint and Orthoptics, Ophthalmic Nursing and Modern System of Ophthalmology (MSO) Series*, have also been well received.

Dr Khurana has published more than 250 scientific papers in national and international journals of repute. He has also contributed several chapters for postgraduate reference books published in India and abroad. He has also been Editor of Haryana Journal of Ophthalmology, Indian Journal of Strabismus and Pediatric Ophthalmology (IJSP), and North Zone Journal of Ophthalmology. He was awarded WHO Fellowship for higher studies at Moorfields Eye Hospital, London. He was also selected for a course and awarded Certificate in Tropical Ophthalmology at International Centre for Eye Health, Institute of Ophthalmology, University of London, UK. He has been honored with Distinguished Author Award by the Federation of Educational Publishers of India, HOS Award for Excellence in Ophthalmology, Excellence Award by Strabismological Society of India, Gold Medal by Intraocular Implant, Refractive Society of India, Lifetime Achievement Award by HOS, Uttarakhand State Ophthalmological Society (UKSOS), North Zone Ophthalmological Society, and International Society for Manual Small Incision Cataract Surgery. He has also been honoured with PN Sinha Oration Award by Bihar Ophthalmological Society (BOS) and Fellowship of All India Collegium of Ophthalmology (FAICO).



If any reader wishes to share feedback, suggestions, updates, and errata, please scan the QR code and fill the google form.

Printed in India

Available at all medical bookstores
or buy online at www.jaypeebrothers.com



JAYPEE BROTHERS
Medical Publishers (P) Ltd.
EMCA House, 23/23-B, Ansari Road,
Daryaganj, New Delhi - 110 002, INDIA
www.jaypeebrothers.com

Join us on [facebook.com/JaypeeMedicalPublishers](https://www.facebook.com/JaypeeMedicalPublishers)

Shelving Recommendation
OPHTHALMOLOGY

ISBN 978-93-5696-333-7

